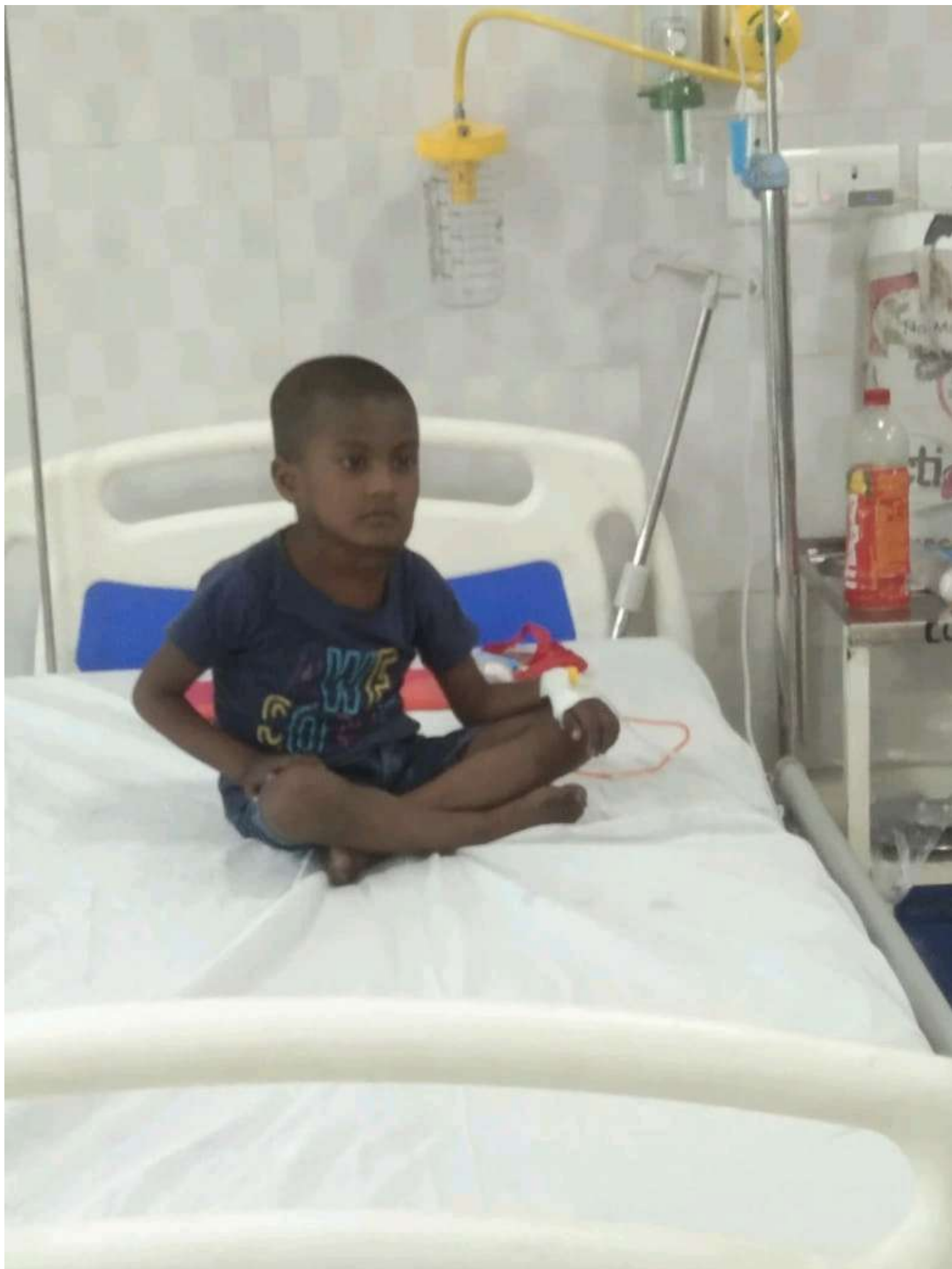
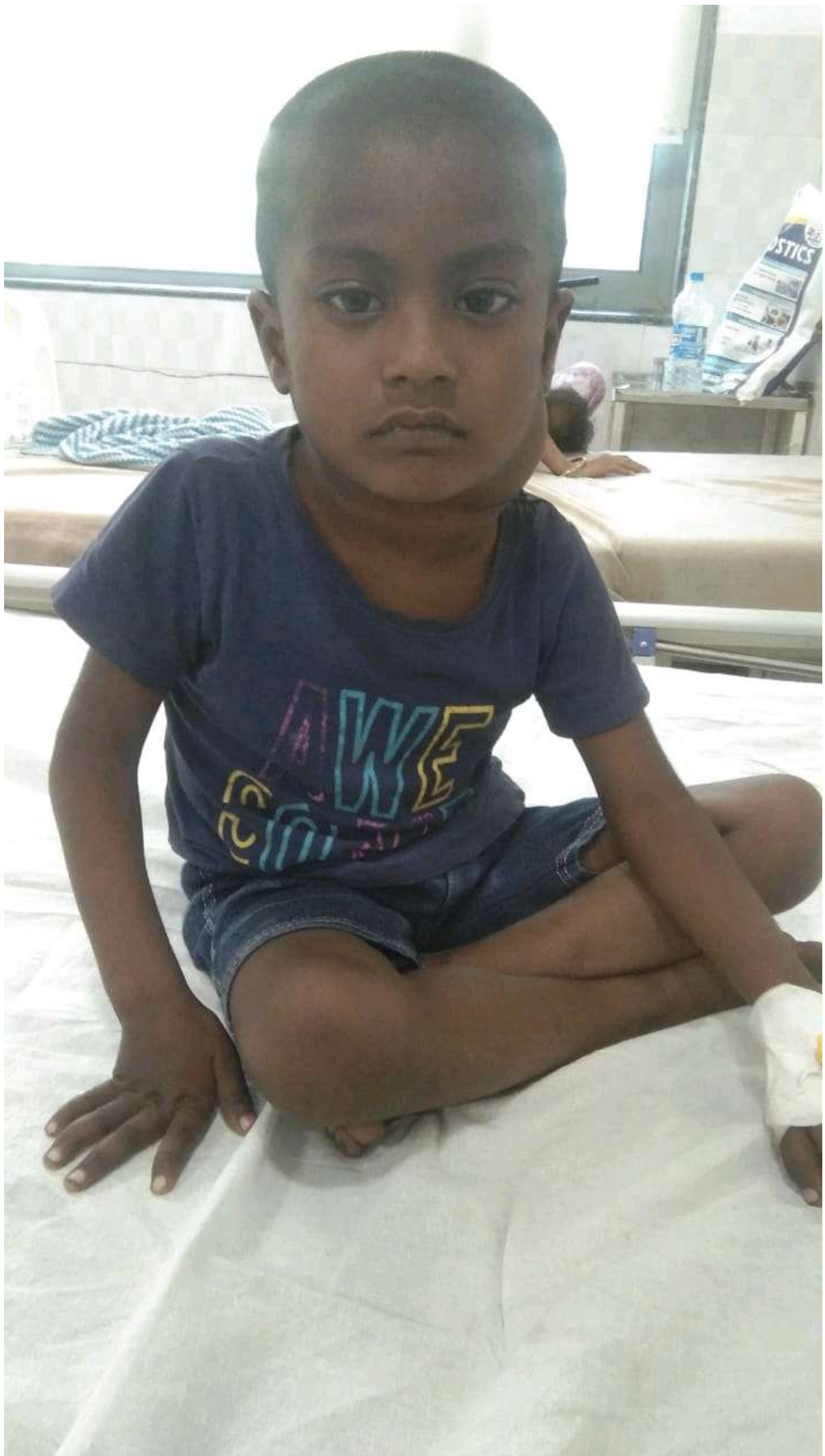







Laboratory Report at HCTS Confirmatory Facilities (SA-ICTC)  
Delhi State AIDS Control Society



Laboratory Test Report form for HCTS Confirmatory Facility

Name & Address of SA-ICTC  ICTC  
Lady Harding Medical College  
New Delhi MC 6550

Name: Surname \_\_\_\_\_ Middle name \_\_\_\_\_ First Name Md. Ameen  
Age: 5 (years)

Gender:  Male  Female  Transgender  
PID No.: GCSAICTCDLNEW008 2607559 Lab ID No.: 07559

Date & Time of Blood Drawn: 6/5/26 (DD/MM/YY) 11:25 AM (HH:MM)

Test Details :

- Specimen type used for testing (tick one):  Serum /  Plasma /  Whole Blood
- Date & Time of specimen tested: 6/5/26 (DD/MM/YY) 2:30 PM (HH:MM)

Note:

- Column 2 and 3 to be filled only when HIV 1 & 2 antibody discriminatory test(s) used
- No cell has to be left blank; indicate as NA wherever not applicable

| Column 1              | Column 2   | Column 3   | Column 4                                       |
|-----------------------|--|--|--|
| Name of the HIV kit   | Reactive/Nonreactive (R/NR) for HIV-1 antibodies | Reactive/Nonreactive (R/NR) for HIV-2 antibodies | Reactive/Nonreactive (R/NR) for HIV antibodies |
| Test I: <u>avanta</u> | <u>NR</u>  | <u>NR</u>  | <u>NA</u>                                      |
| Test II: <u>/</u>     | <u>/</u>   | <u>/</u>   | <u>/</u>                                       |
| Test III: <u>/</u>    | <u>/</u>   | <u>/</u>   | <u>/</u>                                       |

Interpretation of the result: Tick(✓) relevant

- Specimen is negative for HIV antibodies
- Specimen is positive for HIV-1 antibodies
- \*Specimen is positive for HIV antibodies (HIV-1 and HIV-2; or HIV-2 alone)
- Specimen is indeterminate for HIV antibodies. Collect fresh sample in 2 weeks

\*Confirmation of HIV 2 sero-status at identified referral laboratory through ART centers

Shanti  
6/5/26  
Name & Signature  
Laboratory Technician

Lal Singh  
Name & Signature  
Laboratory In-charge

Name - Ameen

Age - 4yr 9mths

Presentation - Neck Swelling.

CECT - neck - LN level - 2a, 2b, 3, 4, 5  
max - 3.7 x 2.6 cm.

Chest - WNL

Liver/Spleen - Normal.

LN Biopsy - HL (RS+ve, CD20+, CD30+, CD3+)

BM - Not Involved.

Echo - Normal. EF - 64%.

HEV/HBV/HCV - NR.

Stage - I / Non Bulky.

Risk - Early Stage.

11

क्र. सं. / Pat. No.      लिंग / Gender      CR No.      एकाई / Unit

Date:

11/11/2023  
 11/11/23 Advised on Discharge

Diagnosis

Plan: Excision Biopsy & HPE followed by IHC for definite opinion.

Issues

- case discussed with Dr. Mukesh Chauhan Sir telephonically by Dr. Piyush Jain Sir [Med. Pediatrics] for Lymph node biopsy & further management. ∴ Refer to Kalawati Hospital & LHMC.

Examination Findings

वरिष्ठ रेजिडेंट के हस्ताक्षर  
 Signature of Senior Resident

कनिष्ठ रेजिडेंट के हस्ताक्षर  
 Signature of Junior Resident

Treatment & Plan

इकाई प्रमुख  
 Head of the Unit

*D. D. Lavanyam*  
 DR. D. LAVANYAM  
 M.D. (D.C. Pediatrics)  
 GENERAL OFFICER IN CHARGE  
 Kalawati Saran Children's Hospital

Signature  
 Name of JR/SR

रोग का संक्षिप्त विवरण / Brief Clinical History & Examination :

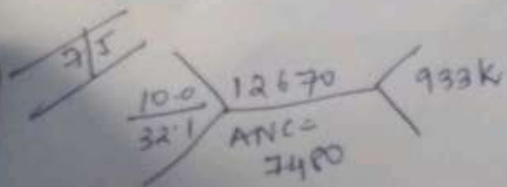
K/10 HL stage I non bulky

↓  
admitted for chemo  
chemo given  
as per protocol

↓  
stable

↓  
D/s.

जाँच / Investigation :



NA/K - 144/5

Ur/W - 20/0.4

Si/T/P - 0.2/0.1

AST/ALT - 11.7/9.1

AU - 252

TP/SA - 7.8/3

CA/T - 9.3

PO4 - 5.42

C

किया गया उपचार / Treatment Given :

chemo 1st cycle given (ABVD) Jugular port set

छुट्टी के समय परामर्श / Advise on Discharge :

1) chlorhexidine MW / candid MP.

2) T. Lanzol Jr 15mg po qd ABVD x 3 days.

3) T. Emset (4mg) 1/2 tab po qd.

4) ~~Aspirin~~ Paracetamol (125/5) 6ml po qd if Temp  $\geq 100.4^{\circ}C$

5) N/V in Hemat day care on 22/5/20 for ABVD 3rd cycle


↓ CBC / LFT in RF

छुट्टी के बाद ओ.पी.डी. में ..... / ..... पर सुबह 9.00 बजे कमरा नं. .... में आएँ।

छुट्टी के बाद ..... स्पेशल क्लिनिक में 2.00 बजे कमरा नं. .... में आएँ।

अगला टीकाकरण ..... तारीख .....

वरिष्ठ रेजिडेंट चिकित्सक के हस्ताक्षर  
Signature of Senior Resident

  
Dr. Anjali K. G.  
कनिष्ठ रेजिडेंट चिकित्सक के हस्ताक्षर  
Signature of Junior Resident

(111)

Urgent

कलावती सरन बाल चिकित्सालय

KALAWATI SARAN CHILDREN'S HOSPITAL

बंगला साहिब मार्ग, नई दिल्ली-110001, Bangla Sahib Marg, New Delhi-110001

क्लीनिकल हिमेटोलॉजी लेब  
CLINICAL HAEMATOLOGY LAB

|                         |               |                          |        |          |  |
|-------------------------|---------------|--------------------------|--------|----------|--|
| नाम/Name                | Ameen         | आयु/Age                  | 4y6m/M | लिंग/Sex |  |
| C.R.No                  | 11196         | Consultant               |        |          |  |
| Ward/OPD                | Hemat daycare | Unit/Bed No.             |        |          |  |
| Date/Time               | 21/5/26       | EDTA/Citrate/Heparin/Nil |        |          |  |
| Nature of Anticoagulant |               |                          |        |          |  |
| Diagnosis/History       | CBC           | Signature of the Doctor  |        |          |  |
| Today's Lab. Ref. No.   |               | Time of Receipt          |        |          |  |

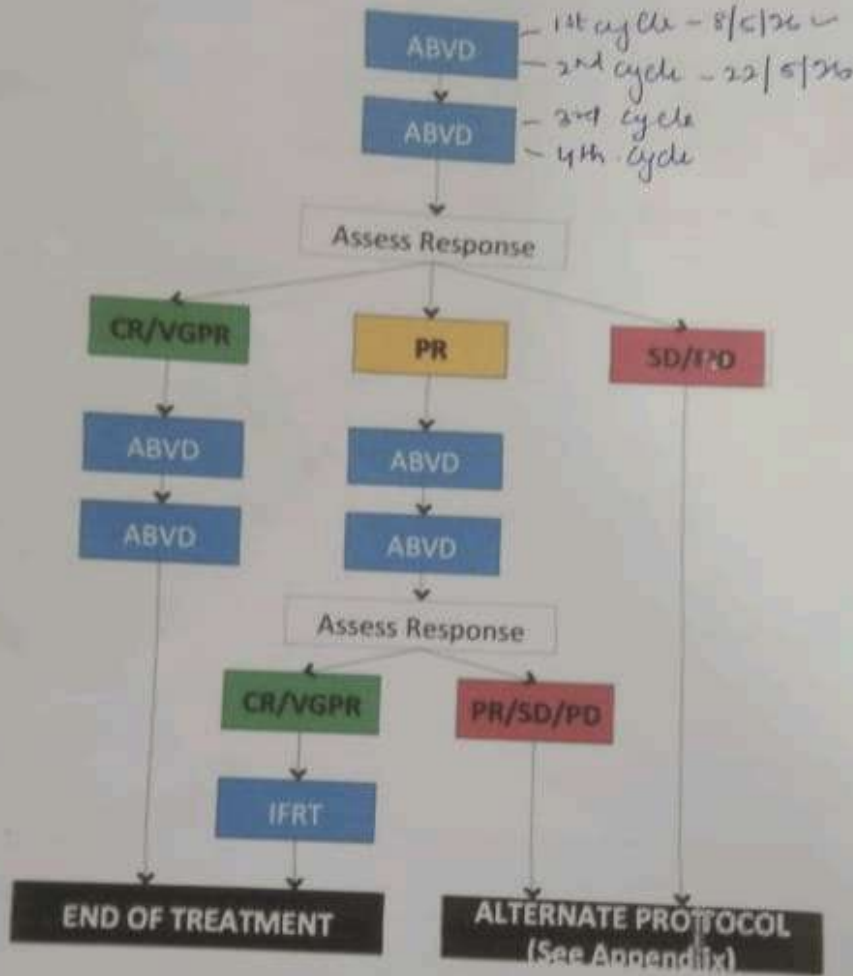
INCOMPLETE FORM IS NOT ACCEPTABLE

Ameen 489M/M  
S/o Md Gulfar

BSA = 0.52m<sup>2</sup>

### 10. TREATMENT (For details refer to Treatment strategy at page No 11)

## EARLY STAGE – NON-BULKY



FNAC  
LN Biopsy

Resp System

CVS

Provisional/Clinical Diagnosis: HL stage I  
non bulky

Basic Hematology Data (At admission)

- Hb. 10.2 gm/dl
- TLC 12670 /mm<sup>3</sup>
- DLC: N 57% L 24% E 4% M 11% B ... Myleo ... Meta ...  
Blasts ... % n RBC ... /100wbc
- Platelets 922k /mm<sup>3</sup>
- Smear Exam ...

• BMA (No 182/26) --- Report  
(3/4/26) Smear are apantular  
& paucicellular showing a  
few hematopoietic cells.

Morphological Subtype ...

Special Stains

- MPO ...
- PAS ...
- Peroxidase ...
- Other ...

Immunophenotyping ...

Chromosomal studies

- Numerical ...
- Structural ...
- BCR-ABL ...

BM biopsy (No) Imprint report ...

• BM Biopsy report (182A/26): 3/4/26 - Erythroid - normoblastic  
myeloid @ megakaryocyte adequat  
en

CSF

CNS Status

• FNAC (No F1376/26) 7/3/26 Sp Hodgkins lymphoma

# FNAL

- LN Biopsy: (No. 3274, A/26)  
    ) CD30 ⊕ | RS all CD15 ⊖ | CD20 ⊕ | CD3 ⊕
- D 8 PS Absolute blast count (exact number).....
- D 14 marrow: (write percentage of blasts).....
- OTHER TESTS
- Mx test Non reactive CXR - WNL 1/5/26
- HIV HR ECHO: WNL
- HbsAg } send 7/5/26
- HCV } send 7/5/26
- LFT: Bil T 0.2 D0121 SGOT 11 SGPT 9 ALP 252
- KFT Urea 20 Creatinine 0.4 Uric Acid
- S Calcium 9.3 Phosphorus 5.42 Potassium 5
- CXR WNL
- Skeletal Survey.....
- USG Abdomen.....
- CT neck chest Abdomen (9/4/26)  
    multiple discrete heterogeneously enhancing  
    neck lymph node at level 1a/1b/3/4/5  
    on ⊕ side forming large LN mass
- PET Scan (date).....
- MRI.....

Diagnosis: HL stage I  
non-bulky

**HEMATOLOGY CASE RECORD**  
**DIVISION OF PEDIATRIC HEMATO-ONCOLOGY**  
**KALAWATI SARAN CHILDREN'S HOSPITAL, DELHI**

Name Md Ameen Age/Sex 4y 9m/M  
Father's Name Md Gulshan Date of Admission 7/5/26  
Address JJ colony Bhawana E block - 5  
Juggi NO-30 Narela Delhi  
Ph./ Mob.: 8447635364  
Blood Group \_\_\_\_\_ Weight 10.6kg Height 94cm Surface Area 0.52m<sup>2</sup>

**SYMPTOMS:** (mention duration of each symptom)

- Fever.....
- Pallor.....
- Skin bleeds.....
- Epistaxis.....
- Other bleeds.....
- Lymphadenopathy..... neck swelling
- Bone pains.....
- Joint pain.....
- Eye Swelling.....

**SIGNS**

- Pallor.....
- Bony Tenderness.....
- Gum Hypertrophy.....
- Skin bleeds.....
- Lymphadenopathy (size/ sites)..... LN cervical level 2a/2b | 3/4/5
- Joint swelling.....  max size 3.7x2.6cm
- Liver (cms)..... WNL > mid-umbilicus...yes/ no.....
- Spleen (cms)..... WNL > mid-umbilicus yes/no.....
- Other lump(s).....
- Testes..... Normal
- Meningeal sings/Focal Neurological Deficit.....
- Fundus..... WNL

8/2024

|                      |                      |               |
|----------------------|----------------------|---------------|
| Name: Ameen          | Sex-45YM             | Reg - 8150    |
| Hospital: KSCM       | Ward: U3C2           | Dr. Incharge: |
| Case No-             | Smear No-F-1379/26   |               |
| Received on -07/3/26 | Reported on - 9/4/26 |               |


**FNAC from left cervical swelling (2737-42/260)**

CALLA

Smears are highly cellular showing predominantly mononuclear RS, with few binucleate RS cells in polymorphous lymphoid background consisting of small mature lymphocytes, few eosinophils, plasma cells and neutrophils.

Features are suggestive of Hodgkin's lymphoma.

**Advice:** Correlation with Histopathology for Confirmation.

  
Dr. Jyoti Garg / Dr. Gurpreet (SR)

Assistant Professor

09/04/2026

### Data Collection Proforma

## A Collaborative Protocol for Newly Diagnosed Indian Childhood Hodgkin Lymphoma patients (InPOG-HL-01)

Hospital Name/ Code: \_\_\_\_\_  
 City: \_\_\_\_\_

Patient's name: Ameen Unique ID: \_\_\_\_\_

Age: 4y 9m Sex: male Hospital No: \_\_\_\_\_

Permanent address/city/village: JJ colony Bhanawa Juggi-30/Narada

Date of birth: \_\_\_\_\_ Date of diagnosis: 7/5/20

Informed consent given: YES  NO

HL subtype: CD30+ Stage: I/nonbulky  
classical

#### BASELINE PARAMETERS

Weight: 10.6 (kg) Height: 94 (cm)  
 Hb: 10.3 g/dl TLC: 12670 /cmm Platelet count: 933k  
x10<sup>9</sup>/cmm  
 Neutrophil percentage: 59 % Lymphocyte percentage: 24 %  
 ESR: \_\_\_\_\_ mm at 1<sup>st</sup> hour LDH: \_\_\_\_\_  
 Albumin: 3 Alkaline phosphatase: 252

#### STAGING DETAILS

In addition to clinical history and examination, which of the following modalities were used to stage the child's HL (tick all that apply)

- |                      | Done                                |                |
|----------------------|-------------------------------------|----------------|
| Chest X-ray          | <input checked="" type="checkbox"/> | _____          |
| CT scan chest        | <input checked="" type="checkbox"/> | _____          |
| CT/MRI whole abdomen | <input type="checkbox"/>            | _____          |
| Ultrasound abdomen   | <input type="checkbox"/>            | _____          |
| PET-CT               | <input type="checkbox"/>            | _____          |
| Bone marrow biopsy   | <input checked="" type="checkbox"/> | _____          |
| Other                | <input type="checkbox"/>            | Specify: _____ |

Swelling: YES  NO   
 B symptoms present or not: YES  NO



भारत सरकार  
Government of India



Issue Date: 21/11/2011



साहना  
Sahana  
जन्म तिथि/DOB: 01/01/2003  
महिला/ FEMALE

2026 1228 4774

VID : 9105 0248 7646 1045

मेरा आधार, मेरी पहचान



भारतीय विशिष्ट पहचान प्राधिकरण  
Unique Identification Authority of India



पता:  
C/O मोहम्मद गुल्फाम, ई-30 जेयूजीआई नं, जे जे  
कॉलोनी, बवाना, उत्तर पश्चिमी,  
दिल्ली - 110039


Address:  
C/O Mohammad Gulfam, E-30 JUGGI NO, J J  
colony, BAWANA, North West Delhi,  
Delhi - 110039

Download Date: 22/12/2021



2026 1228 4774

VID : 9105 0248 7646 1045



1947



help@uidai.gov.in



www.uidai.gov.in